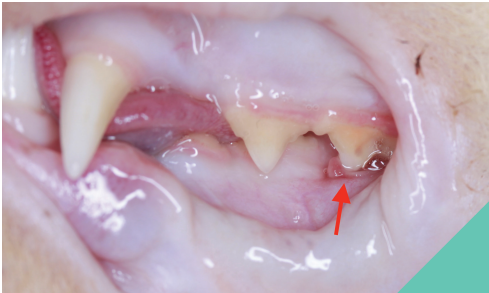


MALOCCLUSION

MALOCCLUSION IS DEFINED AS THE WRONG POSITIONING OF TEETH WHEN THE JAWS ARE CLOSED. IT IS RELATIVELY COMMON IN BOTH DOGS AND CATS.

The position of the teeth and the length of the jaws are genetically controlled. The original face shape of the dog is that of the wolf, but through selective breeding there is enormous variation in the face shapes seen.

The most important aspect of the relationship between the teeth and jaws, no matter what face shape our pet has, is that when the mouth is closed the teeth do not interact traumatically with the soft tissues of the mouth or other teeth.

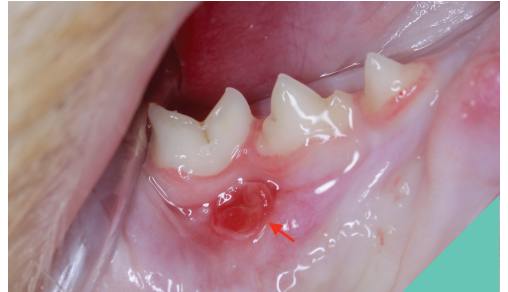

THE TIP OF THE UPPER 4TH PREMOLAR TOOTH IS TRAUMATISING THE LOWER GUM (ARROW).

Abnormal and repetitive contact between teeth may cause inflammation in the pulp of the teeth, which is painful. Additionally, tooth to tooth pressure may cause tooth displacement, which can result in overcrowding. Overcrowding increases the risk of gum disease and trauma of adjacent soft tissues in the mouth.

Contact between teeth and oral soft tissues can result in the development of ulcers, which will be painful. If left untreated these ulcers can worsen and deeper erosion or damage of the underlying tissues is possible.

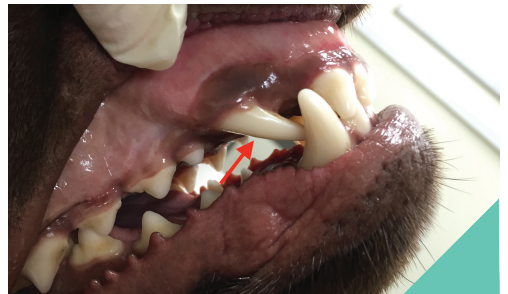This can result in destabilisation of adjacent teeth or even perforation of the palate and communication between the nose and the mouth.



ULCER RESULTING FROM THE TRAUMATIC CONTACT OF THE UPPER TOOTH SEEN IN THE PHOTO ABOVE.

Cats with shorter face shapes are particularly at risk of developing contact between the tip of the last upper premolar tooth and the gum of the lower jaw.

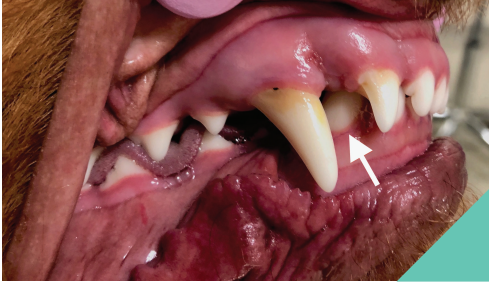Cats are likely to develop growths of infected tissue at the site which they bite on every time they close their mouths, which can be extremely painful. Simple shortening of the tooth crown or tooth extraction is successful in managing this problem.



THE UPPER CANINE TOOTH HAS ERUPTED AT AN ABNORMAL ANGLE AND IS ROTATED (ARROW), PREVENTING CLOSURE OF MOUTH.

MALOCCLUSION

The most common traumatic malocclusion that occurs in the dog results from the lower canine teeth digging into the soft tissues of the upper jaw or palate. This may result from a displacement of one or both lower canine teeth towards the tongue.



THIS DOG'S LOWER JAW IS TOO SHORT AND NARROW WHICH RESULTS IN THE LOWER CANINE TOOTH (ARROW) INJURING THE ROOF OF THE MOUTH.

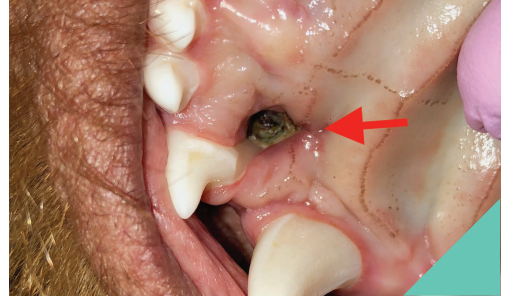
In addition, if the lower jaw is relatively shorter than the upper jaw, the lower canine teeth will strike the soft tissues of the roof of the mouth at its widest point. Identification of inappropriately positioned, maloccluded, lower canine teeth is often first done at a first vaccination consultation. Although the canine teeth causing the problem are baby teeth, they will not be replaced until the dog is five to six months of age, meaning a prolonged period of discomfort during puppyhood.

The canine teeth digging into the soft tissues may also prevent extra growth of the lower jaw compared to the upper jaw, and so improvement in the malocclusion is prevented even if the animal has genetic potential for improvement.

Finally, the adult teeth erupt lingually (closer to the tongue) than the baby teeth and so they may be more severely malpositioned if the baby teeth are still present.

If your puppy is identified with this type of malocclusion, it is likely your vet will advise early extraction of the baby lower canine teeth.

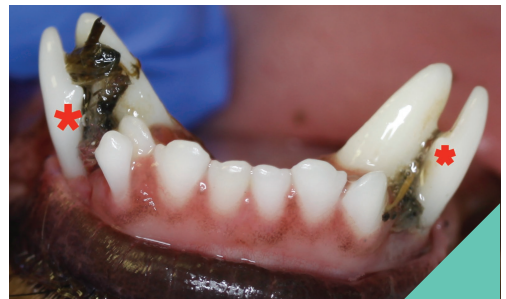If your puppy has had a malocclusion identified with its baby canine teeth, it is important to closely examine the adult teeth when they begin to erupt at between four and a half to six months of age.



THIS IS THE ULCER (ARROW) RESULTING FROM FROM LOWER CANINE TOOTH, SEEN IN THE ABOVE PHOTO. TRAUMATISING THE ROOF OF THE MOUTH. INJURED BONE IN THE ROOF OF THE MOUTH IS VISIBLE AT BOTTOM OF THE ULCER.

If the malocclusion is similar, further treatment is needed.

The adult canine tooth is considered a strategically important tooth and has a number of important functions. Options for further treatment of maloccluded canine teeth include extraction, although this is a definitive treatment and is quite traumatic. Other options include shortening of the crown of the tooth, so that it doesn't injure the soft tissues, or movement of the tooth into a normal position.



RETAINED DECIDUOUS CANINE TEETH (STARRED) HERE ARE STOPPING THE ADULT TEETH FROM MOVING INTO A NORMAL POSITION. ROTTING PLANT MATERIAL CAN BE SEEN TRAPPED BETWEEN THE PERMANENT AND DECIDUOUS TEETH.